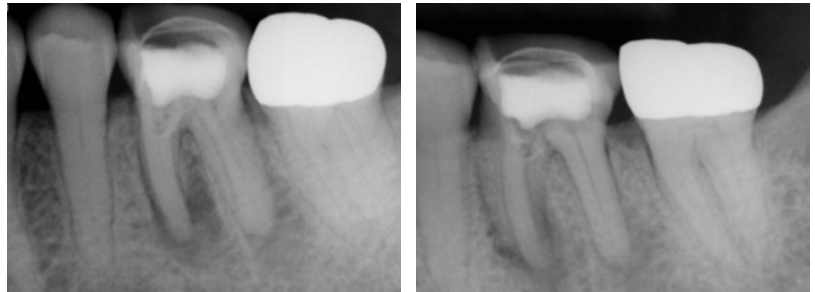
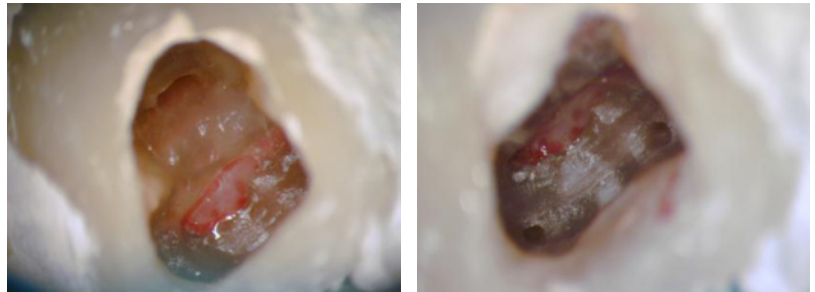


## Furca Perforation

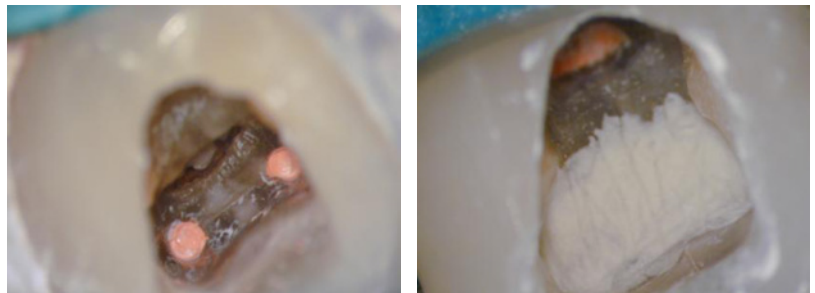RCT on tooth #19 had been previously initiated with a perforation of the chamber floor into a furcation while attempting to locate the calcified mesial canals.



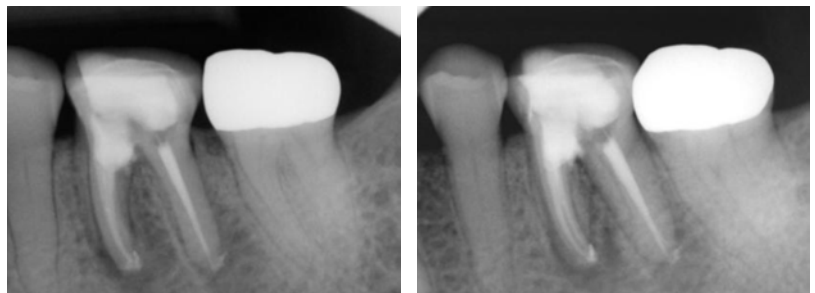
MB and ML canals were located mesial to the perforation site.



Canals are obturated and perforation site repaired with white MTA.

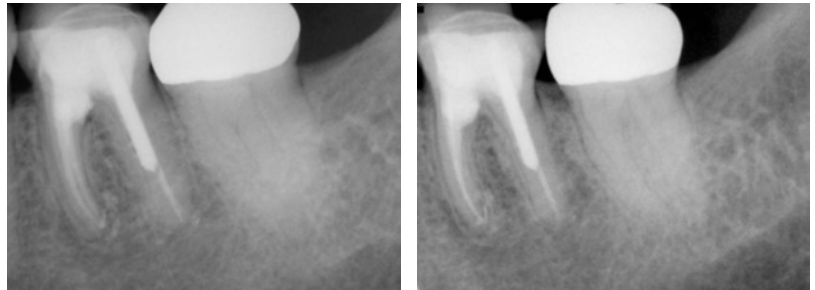


Post Op radiographs.



## Furca Perforation Cont.

One year follow-up.



---

Two year follow-up.

