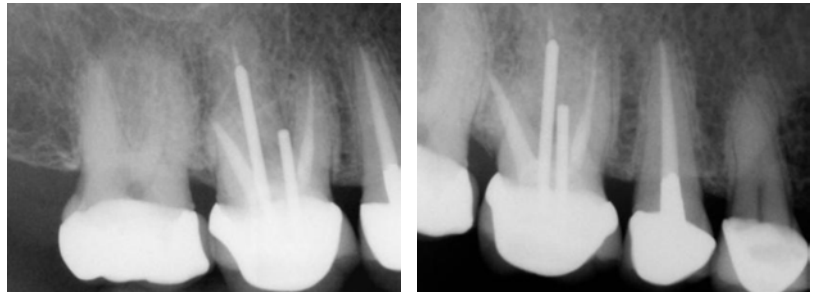
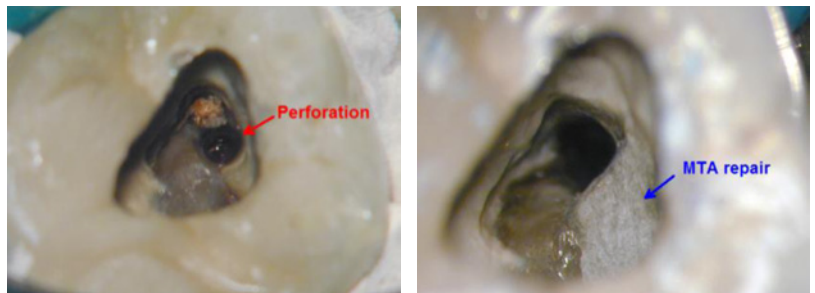


Post Perforation (Furca)

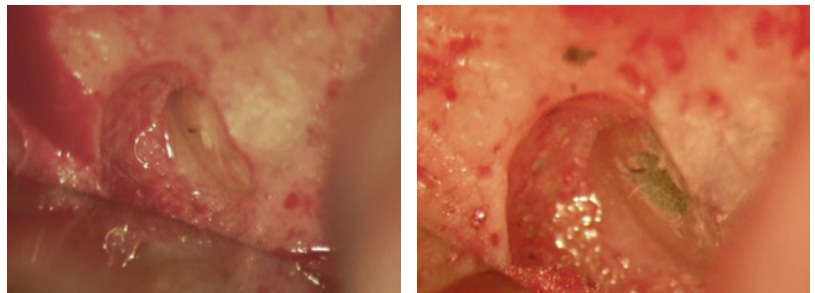
Tooth #3 had a previously treated RCT with perforated chamber floor from post misplacement. RCT had been done 3-4 years ago. The tooth is asymptomatic, but had purulent drainage from a 7mm buccal pocket.



Perforation was repaired and root canal retreated.



During the RETX MB2 site was located, but unable to negotiate the canal to length. Although there was no apparent PA lesion, it was decided that it will be prudent and beneficial for the long term success of the tooth to have a root end surgery on MB root together with a surgical debridement of a perforation repair.



Post Op radiographs.

1. Immediate Post Op
2. Post Op 4 Years

