

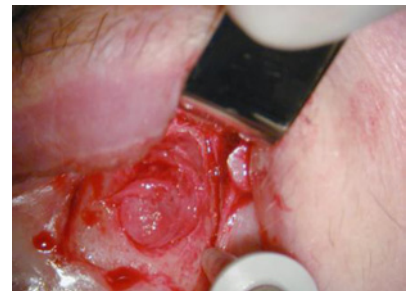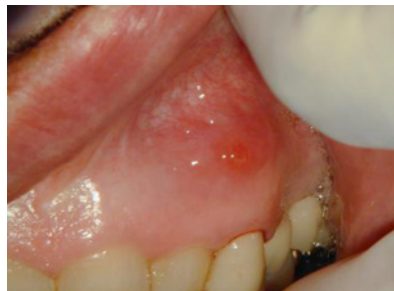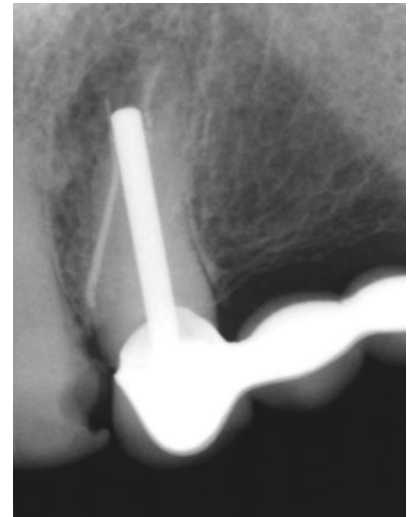
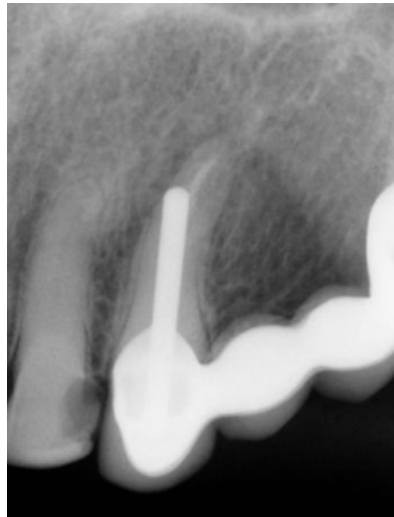
Post Perforation (Root)

Previous RCT and on tooth #11 was done 20 years ago and the FPD was done about the same time. Pt reports that she has tenderness in the apical area for many years, but did not seek any treatment. Pt admits that she does not see her dentist on regular basis. Pt states that swelling and sinus tract occurred about 2 months ago.

Sinus tract is traced to the apical end of the post where there is a radiolucency of 3,5 mm x 5 mm.

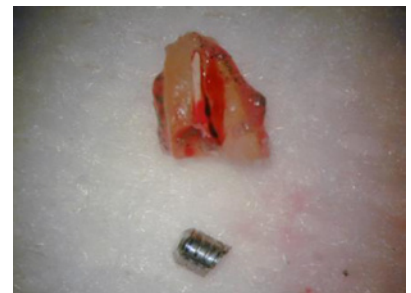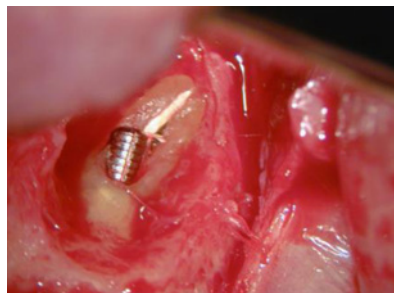Indurated buccal swelling in the apical region of #11 with a sinus tract.

No facial alveolar plate at the apex of tooth #11. A mass of granulation tissue occupies the perforation defect.

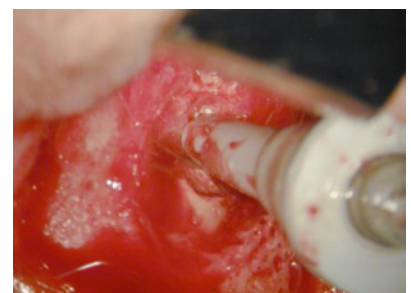
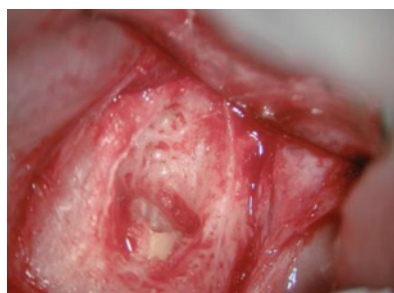

A perforated root end was exposed revealing a post exiting through the perforation.

The root-end and post were resected under constant irrigation.

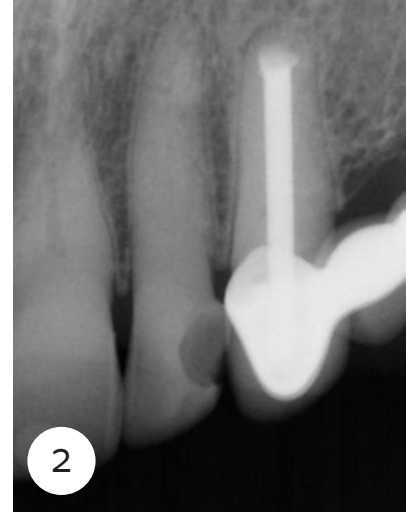
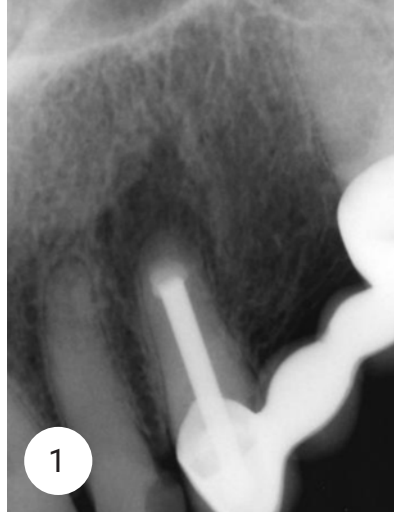

Root-end preparation was made with a modified ultrasonic tip and filled with white MTA..

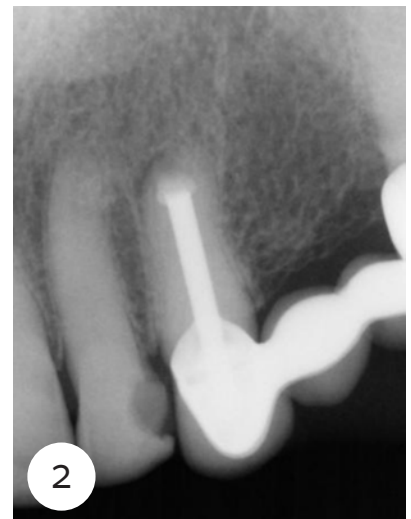
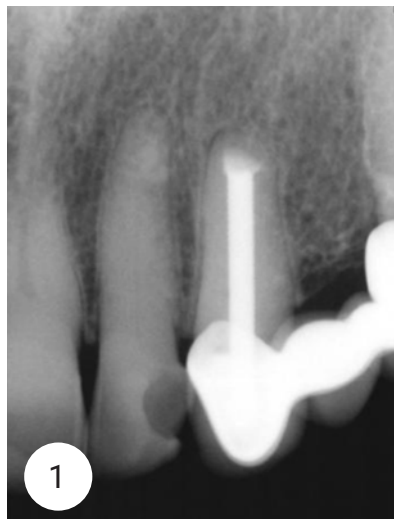


Post Perforation (Root)

1. Surgery Post Op.
2. Follow-up: One year



-
1. Follow-up: Two year
 2. Follow-up: Five year



-
1. Follow-up: Seven year
 2. Follow-up: Nine year

