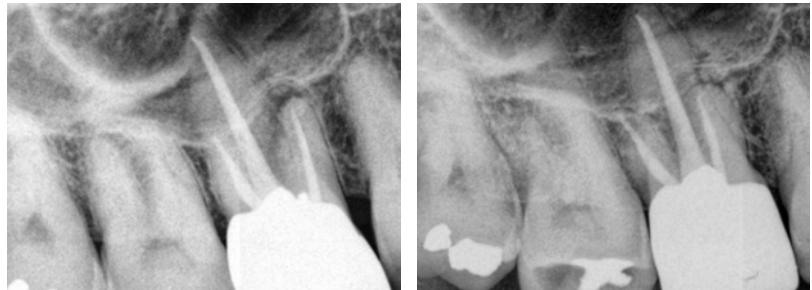
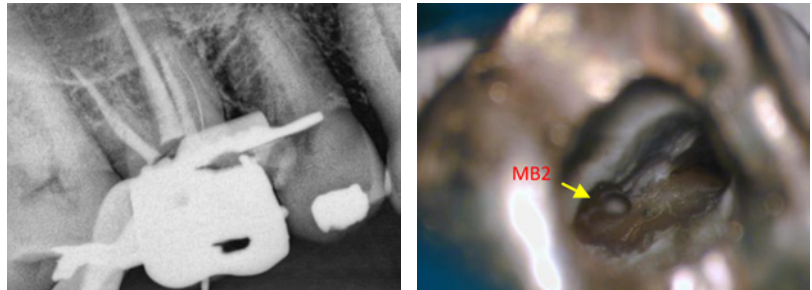


## Non-Surgical Retreatment - Upper Molar

Persistent symptoms on a previously treated RCT tooth #3 with Symptomatic Apical Periodontitis. Periapical radiolucent lesion of 2 x 3.5mm at the MB apex with disruption of the maxillary sinus floor. Mesial shift radiograph shows root canal fill in MB root is not centered, indicating a missed MB2.



MB2 located after troughing with ultrasonics under dental operating microscope (DOM).



MB3 located, branching off the main MB1, on further exploration during interim treatments. Canals were obturated only when the tooth became asymptomatic.



1. After a few interim treatments with  $\text{Ca}(\text{OH})_2$ , healing has already taken place at the time of obturation.

2. Recall 3 years 8 months. PA radiograph shows complete healing and intact sinus floor.

