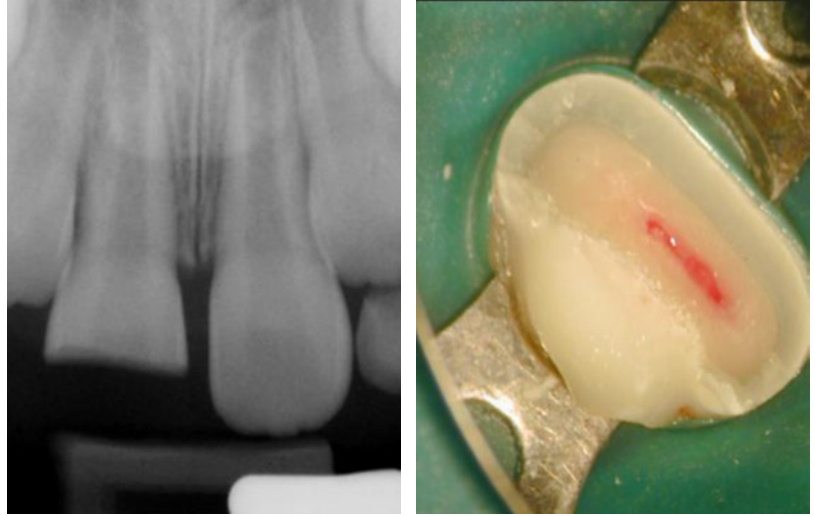


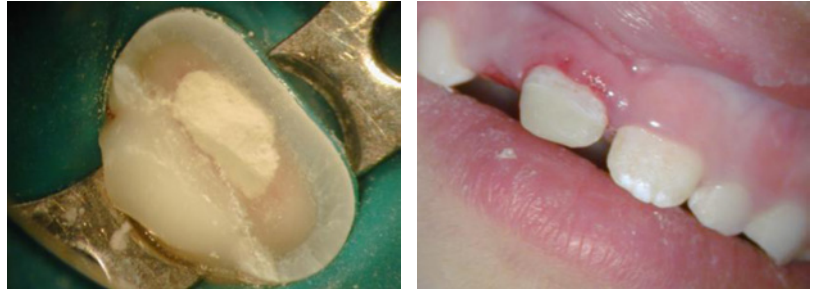## Trauma

Ten y.o. patient has fractured the incisor half of tooth #8 during the playground accident five days ago. It has a horizontal fracture of enamel and dentin at the middle half of the crown exposing the pulp. Tooth #9 is intact. Incomplete root formation with large open apices.



Preserving pulp vitality with partial pulpotomy and MTA.

Restoring fractured coronal tooth structure.



1. Immediate Post Op.
2. One year PO. Root continues to develop - Apexogenesis.
3. Seven year PO with no apical pathosis.

