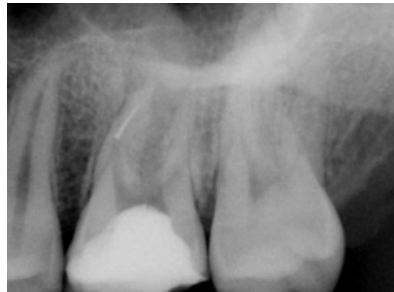

Separated Instrument

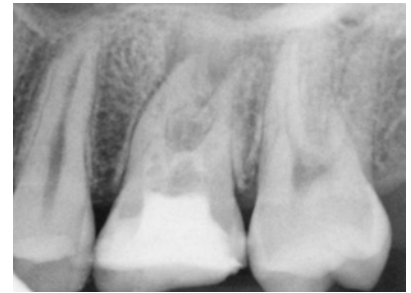
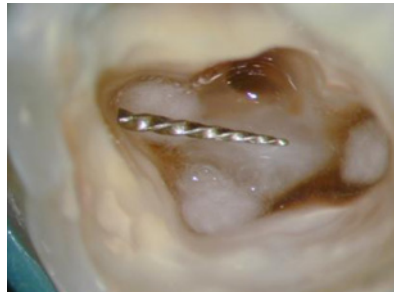
PA radiograph reveals Tooth #3 with a separated file in apical third of MB canal just beyond the curvature. Diffused periapical radiolucency in MB and DB root apices with furca involvement.



SI was visualized in MB2.

Separated NiTi file removed with ultrasonics.

Chemomechanical preparation and placement of Ca(OH)₂ in the canals.



-
1. Immediate Post Op.
 2. Recall 1 year
 3. Recall 8 years 9 months

